

# Conductive Keratoplasty for Presbyopia

Abdul Hamid Awan

*Pak J Ophthalmol 2012, Vol. 28 No. 4*

See end of article for authors affiliations

Correspondence to:  
Abdul Hamid Awan  
Consultant Ophthalmologist  
Shalamar Hospital  
Lahore

**Purpose:** To assess the safety and efficacy of conductive keratoplasty (CK) in the treatment of plano presbyopia.

**Material and Methods:** Twenty plano presbyopic patients (14 women and 6 men) underwent CK in non dominant eye. Mean age was 48.5 year (range 45 to 52 years). The post-operative target refraction for these eyes were minus 1.250 D.

**Results:** Pre-op near refraction was +1.85 D (range +1.50 D to +2.25 D and near vision was J<sub>8</sub> to J<sub>12</sub>. One year after conductive keratoplasty on non-dominant eye, the mean uncorrected near vision was J<sub>1</sub> (range J<sub>1</sub> to J<sub>3</sub>). 90% (18) eyes achieved J<sub>1</sub> and 100% (all 20 eyes) achieved J<sub>3</sub> or better.

**Conclusion:** Conductive keratoplasty for the treatment of presbyopia provided safe and effective results one year following the initial surgery.

A large segment of our population has presbyopic refractive error and refractive surgery procedure. Cataract surgery also produces plano presbyopia when distance viewing monofocal IOLs are used.

For more than 100 years different techniques to shrink peripheral corneal collagen and thereby steepens the central cornea have been developed. Thermokeratoplasty was used in 1980s to produce thermal burns in hyperopic eyes and it showed a lack of predictability and stability, and further development was warranted<sup>1</sup>. Current techniques include thermal holmium: yttrium-aluminum-garnet (LTK)<sup>6</sup>, and conductive keratoplasty (CK). Non thermal, Excimer laser-based techniques for correcting hyperopia include PRK and LASIK<sup>7</sup>.

Conductive keratoplasty is a laser less radio-frequency based collagen shrinkage procedure. The ViewPointCK system (Refractec Inc, Irvine, Calif) uses a probeto deliver low energy, high frequency (350 kHz) current directly into the paracentral corneal stroma at 8 to 16 treatments spots. Striae form between the spots as the collagen contracts, producing a band of tightening that increases the mid central corneal curvature, thereby treating presbyopia. As controlled-released energy flows through the stainless

steel Keratoplast tip (Refracted Inc), the surrounding corneal tissue creates resistance to the energy, resulting in heat production to a temperature of 65°C, causing collagen shrinkage. The Keratoplast tip, with a diameter of 90 µm and length of 450 µm, penetrates the cornea, delivering the current equally from the corneal surface to the end of the tip. The collagen surrounding the entire length of the tip is exposed to the same temperature, creating a column or cylindrical footprint that extends deep into the stroma up to approximately 80% depth.

Conductive keratoplasty has US Food and Drug Administration (FDA) approval for the treatment of 0.75 to 3.00 diopters (D) of spherical hyperopia in patients aged 40 years and is approved for presbyopia for 1.0 to 3.0 D in non dominant eye in March 2004.<sup>2</sup> This study presents the 1-year postoperative results from the first 20 eyes that the author treated with CK. These near plano presbyopic patients underwent unilateral CK in the non-dominant eye to improve near vision.

## MATERIAL AND METHODS

20 eyes of 20 patients (14 females and 6 males) underwent near vision conductive keratoplasty procedure on non dominant eyes in this prospective,

consecutive case series. View Point CK system (Refractec inc California) was used to perform this procedure. Detailed informed consent was obtained from each patient before surgery. Mean age was 48.5 years (range 45 to 52 years).

Eligibility criteria: uncorrected binocular visual acuity no worse than 6/9, manifest refraction spherical equivalent ranging from -0.75 D to +0.75 D and 0.75 D of cylinder. Patients with ocular surface disorders, cataract, glaucoma and any other retinal disorders were excluded from study participation. Patients in good general health with no prior history of ocular surgery were included in the study.

### DOMINANT EYE

Dominant eye was determined using card test. The patient was instructed to sight the 6/60 Snellen E in the examination room. The patients were given 81/4 by 41/2 inch card with 11/4 inch hole in the center. Keeping both eyes open and observing 6/60 E the patient holds the card horizontally at arm's length and centers the card just below the target E. The patient then raises the card so that the distance target is perfectly centered in the middle of the hole in the card the patient then moves the card towards his/her face, all the time keeping the "E" in the center of the hole. The patient repeats these steps several times. The dominant eye is determined by asking the patient to close each eye one at a time keeping the card stationary, and observe which eye focuses the letter E 6/60 at Snellen chart. The eye, which can see the letter E, is the dominant eye and the other eye, which cannot see the letter E by closing dominant eye, is non dominant eye.

This is important in non dominant eye procedures for patients with plano presbyopia, since they will be using their dominant eye for distance vision and binocularly gets blended vision. The loose lens test determines binocular near and distance visual acuity, demonstrates monovision tolerance, clarifies expectations for informed consent, and helps determine the final surgical plan. The loose lens test was performed using loose lens +0.75 D to +2.00 D held in front of non dominant eye while binocularly viewing first the near vision chart held at 14 inches and then Snellen chart to determine patient satisfaction at both near and far distance.

Preoperatively, one drop of Moxifloxacin (Vigamox, Alcon) and 0.5% proparacain (Alcain, Alcon) eye drops were administered two times at 5-

minute intervals. The patient was placed in a supine position. The eye was prepared with pyodine and a specific lid speculum was placed to obtain maximal exposure and provide the electrical return path. The operating microscope was centered over the eye and focused. While the patient fixated on the light from the surgical microscope, the cornea was marked with a gentian-violet-dampened, eight-intersection CK marker that marks the 7-mm treatment zone and makes radial marks that extend from the 7- to 8-mm treatment zone. The Keratoplast tip was placed on the cornea at the treatment markings, perpendicular to the corneal surface. Light pressure was applied until the tip penetrated the stroma to its insulator stop (light touch technique). Energy was applied by depressing the foot pedal. All eyes were treated at the default setting of 350 kHz, 60% power, for 0.6 seconds. A target refraction of -1.25 D to in the non-dominant was selected.

### CONDUCTIVE KERATOPLASTY PROCEDURE

The mechanical effects of CK appear to optimize the prolate curvature of the cornea. The band of circumferential tightening about 3.5 mm from the center of the cornea creates four (1 - 4) distinct zones on the cornea. The apical zone is elevated and slightly steepened. The mid - central cornea is markedly steepened which is meant for near vision. The third zone shows a belt like tightening effect. The peripheral limbal zone is flattened as a result of being tethered to the limbus. After surgery, one drop of Vigamox and one drop of Nevanac (Alcon) were advised for 4 days. Tear natural II (Alcon) were advised as required afterwards. Postoperative examinations were performed at 1 and 7 days and 1, 3, and 12 months. Patients were asked to subjectively evaluate the quality of their vision indicate whether spectacle correction was need for near or Distance vision and report their level of satisfaction.

### RESULTS

In our study, 20 eyes of 20 Plano presbyopic patients treated with CK for near vision correction were followed for 12 months. All eyes were available for follow-up examination at 12 months. Near vision measurements for the treated eyes before and 12 months after surgery are shown in Fig. 2. Before surgery, mean near vision was J<sub>10</sub> (range: J<sub>12</sub> to J<sub>8</sub>). At 12 months after surgery, mean near vision was J<sub>1</sub> (range: J<sub>3</sub> to J<sub>1</sub>), with 90% of eyes J<sub>1</sub> and 100% of eyes J<sub>3</sub>.

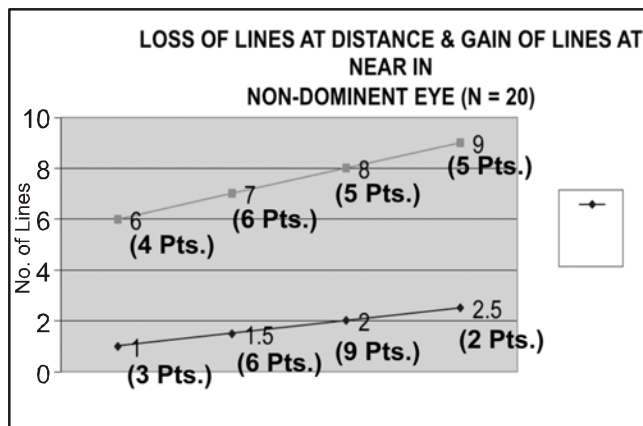


Fig. 1:

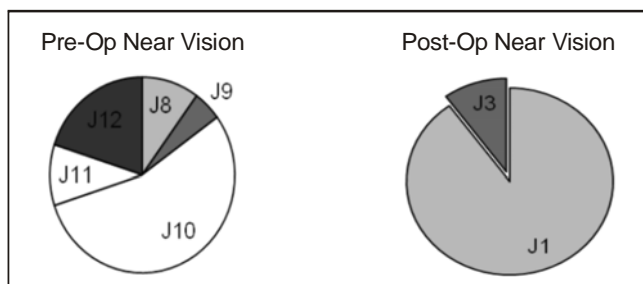


Fig. 2:

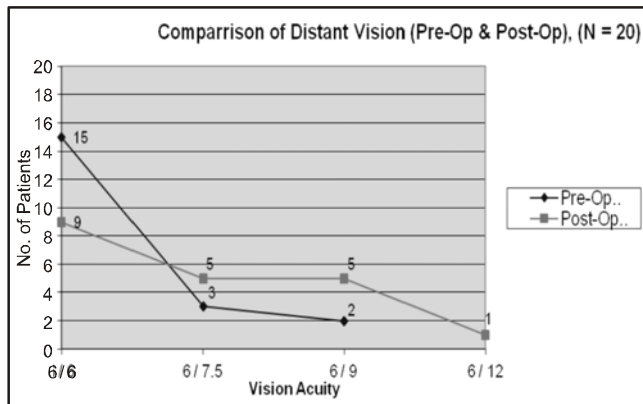


Fig. 3:

Preoperatively mean distance visual acuity was 6/7.5 (range 6/9 to 6/6). At 12 months postoperatively, mean distance visual acuity was 6/9 (range 6/12 to 6/6) Fig 3. Treated eyes lost an average of 1.75 lines (range: 1 to 2.5 lines) of distance visual acuity but gained an average of 7.5 lines (range: 6 to 9 lines) of near vision. Fig 1. Preoperatively, 2 (10%) patient had binocular distance uncorrected visual acuity 6/9 and near vision J<sub>8</sub>. At 12 months after surgery, 90% (18/20) of patients had binocular

distance visual acuity 6/6 and near vision J<sub>1</sub>. Fig. 2. The mean binocular distance visual acuity was 6/7.5 in all 20 patients before surgery and 6/9 one year after surgery. Fig 3. No eye had lost lines of best corrected visual acuity.

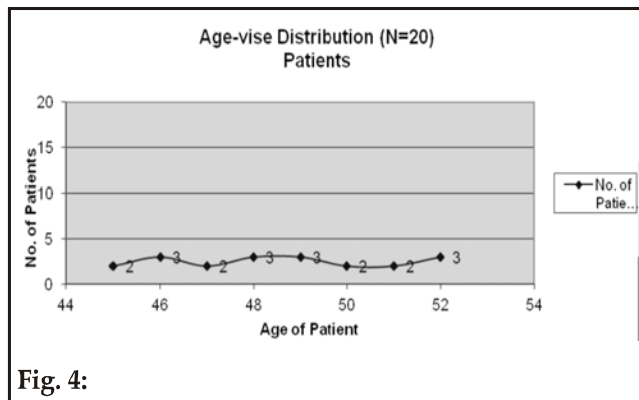


Fig. 4:

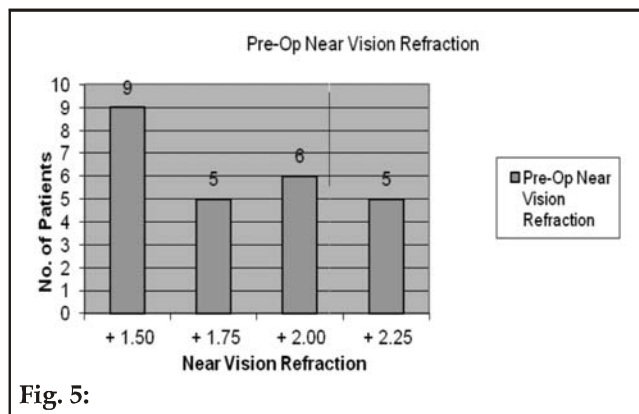


Fig. 5:

All 20 CK-treated eyes were evaluated for stability at 1 month, an overcorrection was observed with a mean of -2.25 D for a final correction of -1.25 D. At 3 months, the mean manifest refraction was -1.50D, representing a decrease of the 0.70 D from 1 month. The 1 - year refraction was -1.25 D, target and a 44% regression from the 1-month overcorrection. The rate of regression was low between 3 and 12 months with the mean SE changing 0.050 D per month.

Conductive keratoplasty spots (leukomas) that extend approximately 80% to 90% of the corneal thickness are produced during the treatment. Striae are seen between two adjacent spots by collagen shrinkage, which develop band like effect by connecting all 8 spots results in steepening of Para central prolate cornea meant for near vision without glasses. At one year spots and striae faded gradually

and are not cosmetically visible, but faint CK spots can be seen on slit lamp examination. No complications occurred during the procedure or postoperatively in all 20 eyes.

## DISCUSSION

Clinical results 1 year after Near Vision CK indicate that this is a promising technology for presbyopia. All 20 patients in this study, ranging in age from 45 to 52 years, were reluctant to wear reading glasses. They belong to the category of plano presbyopes, defined as having 0.75 D of emetropia with no more than 0.75 D of cylinder, having significant presbyopic symptoms. Binocular distance vision was 6/6 in all 20 patients but they were dependent on near vision glasses for all daily life activities.

All patients achieved improved uncorrected near vision after CK treatment. 100% of patients achieved J<sub>3</sub> or better near vision with 90% of patients reading J<sub>1</sub>, while maintaining binocular distant visual acuity of 6/6 in 100% of patients at one year after procedure.

An overcorrection observed initially following CK treatment, was reduced by early hyperopic regression. The rate of regression decreased between 3 months and 1 year after surgery.

Pallikaris<sup>4</sup> et al. reported that CK for low to moderate hyperopia had demonstrated more stable results than PRK and similar stability as LASIK for hyperopic correction. Our results are comparable with previous study of Jason E. Stahl<sup>3</sup> with similar results.

McDonald et al<sup>5</sup> reported the MRSE changed 0.05 D in 89% of eyes between 3 and 6 months postoperatively in the CK presbyopia FDA clinical trials. The stability of CK for the correction of presbyopia should be similar to CK for the correction of hyperopia.

## CONCLUSION

Conductive keratoplasty is a valuable addition to refractive surgery. For plano presbyopia it appears to be a safe, effective and predictable procedure, for patients who want to see without glasses at near but it has to be done after loose lens testing and detailed informed consent.

## Author's Affiliation

Dr. Abdul Hamid Awan  
Consultant Ophthalmologist  
Shalamar Hospital  
Lahore

## REFERENCES

1. **Newmann AC, Sanders D, Raanan M.** Hyperopic thermokeratoplasty: clinical evaluation. *J Cataract Refract Surg.* 1991; 17: 830-8.
2. United States FDA PMA P010018: Refractive ViewPoint CK System. Physician's Reference Guide for Treatment of Presbyopic Emmetropes and Hyperopes to Improve Near Vision Utilizing Conductive Keratoplasty (CK). Irvine, Calif: RefractiveInc. 2004.
3. **Stahl JE.** *J Refract Surg.* 2006; 22: 137-144.
4. **Pallikaris IG, Naoumidi TL, Panagopoulou SI, et al.** Conductive keratoplasty for low to moderate hyperopia: 1-year results. *J Refract Surg.* 2003; 19: 496-506.
5. **McDonald MB, Durrie D, Asbell P, et al.** Treatment of presbyopia with conductive keratoplasty: six month results of the 1 - year United States FDA clinical trial. *Cornea.* 2004; 23: 661-8.
6. **Alio JL, Ismail MM, Sanchez Pego JL.** Correction of hyperopia with non contact HO: YAG Laser thermal keratoplasty. *J Refract Surg.* 1997; 13: 17-22.
7. **Davidorf JM, Eghabli F, Onclinx T, et al.** Effect of varying the optical zone diameter on the results of hyperopic laser in situ keratomileusis. *Ophthalmology.* 2001; 108: 1261-5.